

ODONTOMA IN A NORTHERN MAMMOTH

by H. A. HUNTER and WANN LANGSTON, JR.

ABSTRACT. A fossil odontoma presumably derived from *Mammuthus primigenius* has been collected from late Pleistocene deposits in the Yukon Territory, Canada. Odontomas are not as commonly recognized as some other pathological conditions in extinct vertebrates, but the majority of undoubted cases reported are from Pleistocene proboscideans of North America and Asia. Some reports in other mammalian orders from other regions may be questioned. Owing to a very inadequate record no correlations can yet be shown between the incidence of odontoma and possible environmental causative factors, either in living or extinct vertebrates. The distribution of odontomas in living animals (mammals and teleost fishes) suggests that the lesions probably occur more often in the fossil record than existing reports suggest.

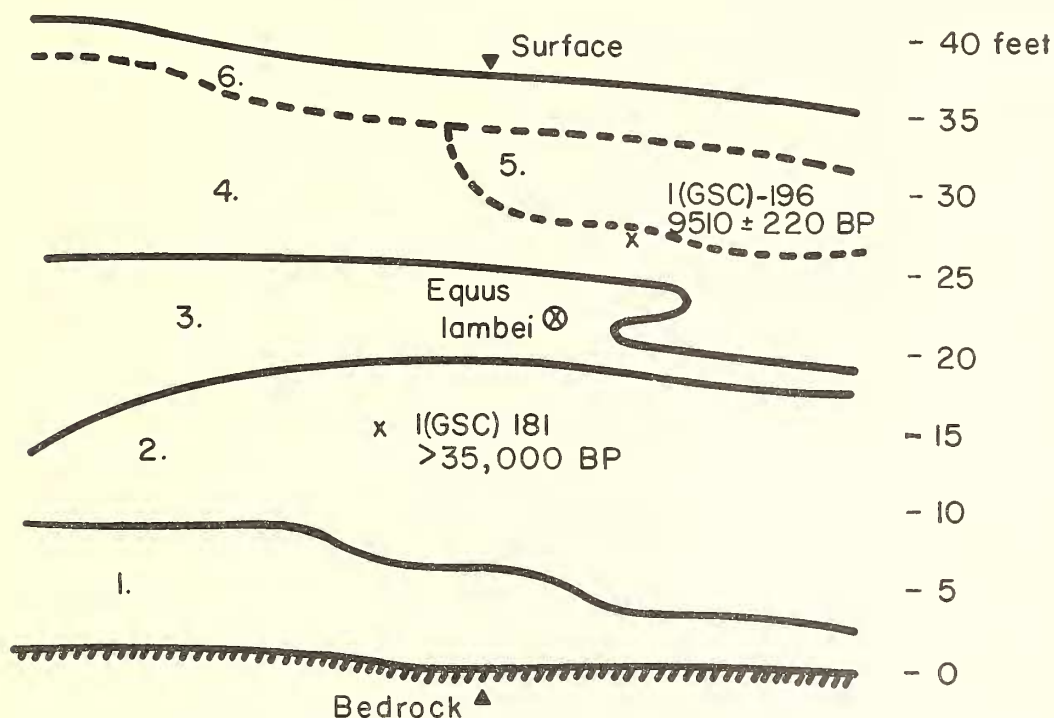
ODONTOMAS are a loosely knit group of lesions that have, as a common factor, their origin from cellular tissues related to tooth formation. They all exhibit degrees of overgrowth, but, whereas some are true neoplasms in the fullest sense of the word, others are really hamartomas representing a faulty overgrowth of tissues that belong naturally in a given area and hence have a limited growth potential. There are both soft (uncalcified) and hard (calcified) forms. The former, if it occurs, is not likely to be recognized in fossil state. The latter is the group that interests the paleo-pathologist. It contains three forms mostly likely to appear as fossils; viz. cementoma, complex composite odontoma, and compound composite odontoma. For a more detailed classification the reader should consult Gorlin *et al.* (1961).

The composite odontomas are composite in the sense that they contain mature enamel, dentine, and cementum and are further subdivided on the basis that in one, the complex form, the specimen is a single mass, while the compound form occurs as an aggregation of discrete, calcified particles numbering, at times, into the hundreds. Although these lesions are not uncommon in man they are noted only occasionally in other mammals. A few examples have been reported in Pleistocene mammals (see Table 1), but recognition of odontomas in the fossil record is much less frequent than some other pathological conditions.

A small collection of Pleistocene vertebrate remains recently collected in the Yukon Territory contains a large, irregular, cauliflower-shaped object which is identified as a complex composite odontoma. The large size of the specimen and the occasional presence of structures suggesting the layering of mammoth ridge-plates (cheirolites) leaves no doubt that it was derived from a proboscidean. Its association in the field with normal teeth and bones of *Mammuthus primigenius* suggests that it is attributable to the Northern mammoth. Although not unique, this specimen is interesting as an example of an unusual, diagnosable pathological condition in an extinct animal.

Occurrence. The specimen (National Museum of Canada No. 9927) was collected by Messrs. George Fant and Ivor Norbeck, and submitted by O. L. Hughes of the Geological Survey of Canada. It was picked up in the talus at the bottom of a steep face at the Fant and Norbeck placer pit, left limit of Hunker Creek, between Too Much Gold and Gold Bottom Creeks, Klondike District, Y.T. (65° 58' N., 138° 58' W.). The area is unglaciated, and the sediments, though generally frozen, are unconsolidated.

Stratigraphic relationships at this locality are summarized in the accompanying diagram (text-fig. 1) which is adapted from field notes of O.L. Hughes (1960). Of the occurrence Hughes states (pers. comm.): 'Although the mammal bones at this locality appear to be derived from Unit 3 of the sketched section, bones are found elsewhere along Hunker Creek in a unit correlated with Unit 2. There is a strong possibility that bones and other



TEXT-FIG. 1. Schematic diagram of the stratigraphy at the Fant and Norbeck placer pit, Klondike District, Y.T. The mammoth odontoma and other Pleistocene mammal bones were discovered in talus at bottom of section. (1) auriferous gravel, (2) organic silt, (3) silty gravel with *Equus lambei*, (4) organic silt, (5) silty peat with abundant wood, (6) silty peat with little wood. Compiled from data provided by O. L. Hughes, 1962.

remains found in Unit 3 were concentrated during a minor erosional cycle from Unit 2. Locally, where Unit 2 is lacking (eroded?), mammal bones are concentrated at the top of Unit 1 and overlain by silt and peat equivalent to Units 4, 5, and 6.'

A radiocarbon date of 9510 ± 220 years BP has been obtained from peat in the frozen silts above the bone-bearing gravel of Unit 3 (I (GSC)-196) and spruce wood from Unit 2 at this locality is more than 35,000 years old (I (GSC)-181). Thus the bones, if derived from Unit 3, are no younger than late Pleistocene. Associated in the talus with the odontoma and other remains of *Mammuthus primigenius* were horn cores and postcranial elements of several individuals of *Bison* cf. *B. crassicornis*. A well-preserved skull and jaws apparently referable to *Equus lambei* were found *in situ* in Unit 3. These species are characteristic of the latest, Wisconsin, glacial stage in north-western North America. The fact that the horse skull and mandible occurred together and show no effects of

transportation in association with high-energy clastic sediments indicates that this specimen at least had not been reworked from an earlier deposit (barring the possibility that part of a frozen carcass might have been involved). It seems likely therefore that some, if not all of the fossils are of very late Pleistocene age, probably closer to 9,500 years old than 35,000. Perhaps the odontoma is one of these.

Description. The gross specimen (Pl. 101, fig. 1) consists of a single, hard mass approximately twice as broad as it is thick, weighing 10.19 kg. (22.47 lb.). Its dimensional measurements are $31 \times 27\frac{1}{2} \times 17\frac{1}{2}$ cm. The surface is coarsely nodular, the nodules, in turn, being aggregated into large irregular lobular masses. Closer examination of the surface does not reveal any obvious broken facet, which supports the belief that the specimen is whole. The finer details of the surface, allowing for the weathering effect of thousands of years, shows a rough and crevassed appearance. Differences in surface texture are apparent by scratching. There are small areas up to 3 mm. that have a glass-like hardness (enamel), and two other substances of lesser hardness that later proved to be dentine and cementum. The external surface was similar to that of known odontomas.

Plate 100 is an X-ray of the whole specimen. The thickness of the specimen prevents any clear details, but one can see the coarse lobular pattern throughout.

Following the external examination the specimen was sawn in half and the cut surface polished. It appears to be a hodge-podge of the three calcified tissues interspersed with narrow spaces originally occupied by pulp and fibrous connective tissues (Pl. 101, fig. 2).

For purposes of microscopic study, ground sections, approximately 75–100 microns thick, were prepared from small samples cut from the main mass. The entire specimen is a conglomeration of islands of enamel and dentine together with masses of cellular cementum (Pl. 101, figs. 3, 4). Quantitatively, enamel is the least frequent component, constituting less than 5 per cent., while dentine and cementum appear about equal in amounts. There are very few soft tissue spaces to be seen within the mass, they being merely microscopic 'pulpal' tracts in the centres of the dentine areas, or minute spaces between some of the calcified nodules. In studying these spaces for remains of soft tissue, pieces of the specimen were hydrated in normal saline solution, but subsequent microscopic examination failed to reveal any trace of cellular detail.

The three constituent calcified tissues—enamel, dentine, and cementum—appeared histologically normal in ground sections; the dentine, in places, showing well-defined incremental lines.

The histological pattern of the whole lesion is typically that of a complex composite odontoma.

ODONTOMAS IN THE FOSSIL RECORD

Although pathological conditions among fossil vertebrates have been widely noted, most reports are based on bone abnormalities. Only ten fossil odontomas, all of Pleistocene age, are known to us. Of these no more than four cases are considered confirmed. This fossil record is summarized in the following table.

EXPLANATION OF PLATE 100 (opposite p. 662)

FIG. 5. Odontoma in a Northern Mammoth. X-ray of the gross specimen (National Museum of Canada No. 9927). Taken on DuPont Detail GA Screen film at 120Kv. and 100Ma. for $4\frac{1}{2}$ secs.

TABLE 1. Fossil odontomas.

<i>Species</i>	<i>Diagnosis</i>	<i>Locality</i>	<i>Reference</i>
<i>Mammuthus primigenius</i>	Complex composite odontoma	Yukon Territory, Canada	This paper
' <i>Elephas mammonteus</i> '	Simple odontoma	China	Takai, 1939
<i>Palaeoloxodon namadicus</i>	Compound odontoma	Japan	Tokunaga and Takai, 1937
<i>P. namadicus naumanni</i>	Composite odontoma	Japan	Takai, 1939
<i>Mammuthus imperator</i>	? Odontoma	Oklahoma	Stovall and Johnston, 1934
<i>M. trogontherii</i>	? Compound odontoma	France	Pontier, 1930
Elephant	? Odontoma	Europe	Pales, 1930
Bovid	? Odontoma	Europe	"
<i>Equus curvidens</i>	? Odontoma	Argentina	Cabrera, 1934
<i>Macrauchenia patachonica</i>	? Odontoma	"	"

That seven proboscidean odontomas are included is probably owing to the huge size that the lesions sometimes attain in these animals (the Yukon specimen is twice as large as the largest normal *M. primigenius* molar in the National Museum of Canada collections).

The simple (*sic*) odontoma from China is irregularly pyramidal in form and about 1.5 times as wide as a normal mammoth molar. It is supposed to represent a lower tooth. Arrangement of dentine, enamel, and cementum is said to be normal, but the cut section reveals an almost complete absence of organized cheirolites; numerous elongate, vertical tubules of dentine surrounded by thick plicated enamel were present instead. Ridges and grooves seen in lateral aspect suggest normal cheirolites, but these merely reflect serial arrangement of some of the tubules. The entire specimen seems to be enclosed in cementum and there is no indication of wear.

The compound odontoma described by Tokunaga and Takai was dredged from the sea bottom near the island of Kotuti. This lesion involved the first and second lower right molars. The specimen is retained in the mandibular ramus which has undergone considerable hypertrophy in the vicinity of the lesion. Although greatly contorted the basic organization of elephantine molars is recognizable. Interestingly, this odontoma evidently functioned as a molar—its upper surface contains a broad concavity produced by grinding, and the third molar which is normal in shape, size, and position in the jaw has not yet come into use. This lesion is closely related to the complex odontoma, but differs in being a little more mature in terms of morpho-differentiation.

The second Japanese odontoma was recognized by Takai from a description and illustration provided by Makiyama (1938). This is a composite lesion apparently derived from the second and third lower molars. Several normally arranged but much compressed cheirolites form a tooth-like mass which is attached by complicated cheirolite-like structures to the lingual side of the otherwise normal third molar anteriorly. The angle between the two is about 90 degrees. It is not clear whether the odontoma should be regarded as part of the third molar or as a neoplasm fused to it. Makiyama believed it to represent the second molar. As in the preceding case this odontoma functioned as a tooth. Its occlusal surface is faceted by wear and is continuous with the grinding surface of the normal tooth behind. Tips of the cheirolites are worn. A further interpretation

is that it might be a complex odontoma fused to a normal third molar by cementum as a form of concrescence.

The specimen from the Yukon is larger by far than any of these oriental examples. Its morpho-differentiation is less mature since only the slightest suggestion of elephantine dental organization can be seen in the cut sections. There is no trace of wear and it appears certain that this odontoma never participated in mastication. A piece of normal spongy bone was 'trapped' by growth of some of the irregular papillary processes and is still held in place by them in the fossil. Probably therefore the lesion was enclosed in bone, but whether in the upper or lower jaw is unknown.

The specimen described by Stovall and Johnston attracted attention because of the great hypertrophy of the alveolar part of the mandible, which is reminiscent of the specimen of *Palaeoloxodon namadicus* figured by Tokunaga and Takai. A seemingly normal molar was functional at the time of death. However, Stovall and Johnston note what they believe to have been a fracture of the molar at which opposing surfaces of the cheirolites are worn. The small posterior portion of the tooth is deeply buried in the alveolus and appears to lack surficial features that are ordinarily present on unerupted mammoth teeth. A wide necrotic sinus occurs posteromedially in the wall of the mandible about opposite this part of the tooth. It is possible that the small posterior segment of tooth is in fact an odontoma.

The Pontier specimen is thought to represent a left DM³. A molar which appears normal in other respects has lightly attached to its roots a '... bourgeon ... formé d'une série de lames légèrement incurvées avec sustentations radiculaires ... implantée entre le groupe de racines antérieures et le talon postérieur de la dent fonctionnelle'. The 'bourgeon' has two talons of its own and is said to contain not more than three ridge plates. Whether its dental components show a lack of organization is not stated. Pontier (pp. 3-4) explains this anomaly as '... une pré molaire, reste atavique d'une disposition existant chez les ancêtres des éléphants'. The description and illustration do suggest the possibility of an odontoma, but it is not impossible that this may be a case of concrescence between a supernumerary tooth and one of the normal complement.

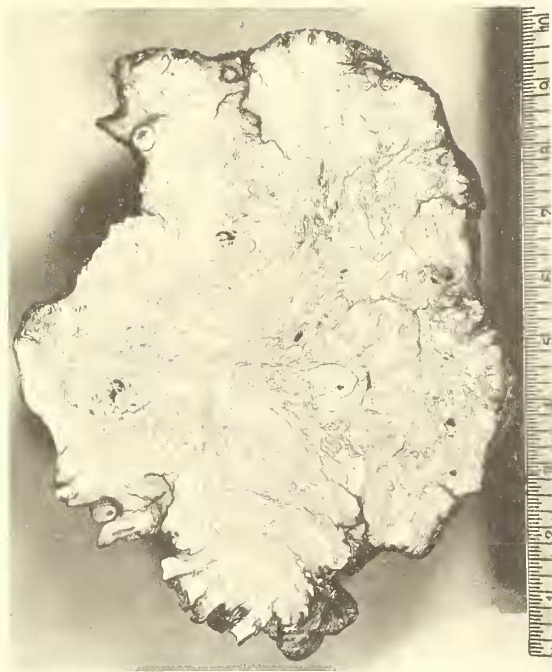The elephant specimen reported by Pales is especially interesting because it was housed loosely in a cavity at the base of a tusk. The mass is ovoid or ellipsoidal in form and its surfaces are longitudinally striated. It bears no resemblance to a normal proboscidean molar, but the surficial markings are suggestive of the configuration of the bases of tusks. The bovid specimen reported by the same author is a curious excrescence on a tooth which he identified as an odontoma. But Pales adds that veterinarians who examined

EXPLANATION OF PLATE 101

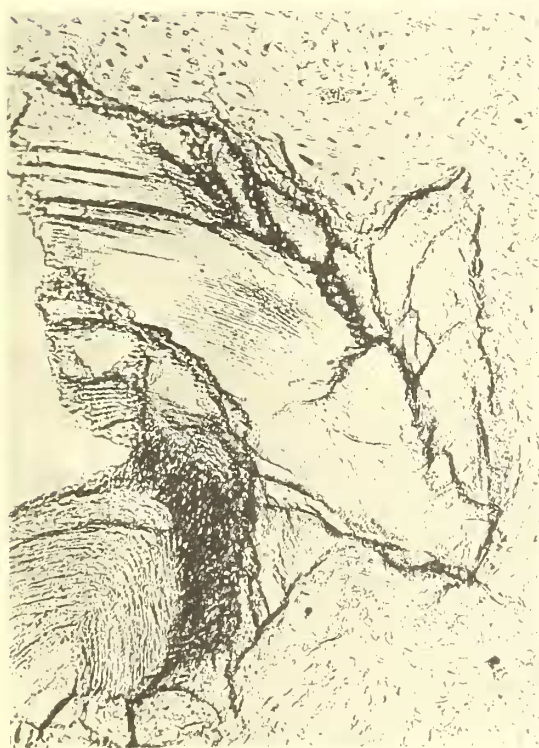Odontoma in a Northern Mammoth. 1. Gross specimen (National Museum of Canada No. 9927) showing the nodular surface and absence of wear facets. The opposite side is essentially similar. On the lower right side are a few projections slightly suggestive of tooth structure. 2. Polished cut surface through the centre. The overall lack of morpho-differentiation is apparent. The suggestive tooth structures are here seen on the lower left side of the picture. Scale in inches. 3. Photomicrograph of a ground section showing a small spicule of enamel and its rod structure. The surrounding tissue is cellular cementum. (Enamel shows numerous artefact fractures produced during grinding.) $\times 35$. 4. Photomicrograph of a ground section showing typical dentinal tubules and dentine matrix surrounded by cellular cementum. $\times 35$.



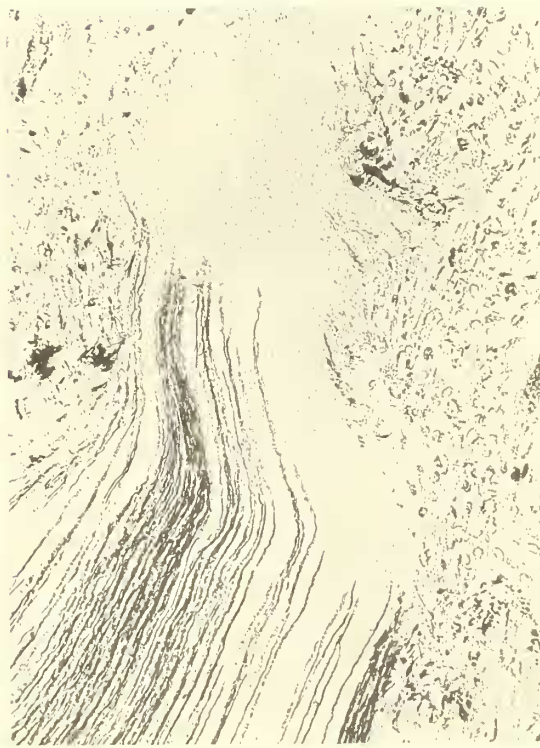1



2



3



4

the specimen declined to make a diagnosis on the grounds that nothing similar had been seen in living animals.

The *Equus curvidens* specimen reported by Cabrera occurs at the site of PM¹ in a very old individual. His *Macrauchenia* specimen is a worn M². Neither specimen is comparable to the lesions described above in proboscideans, and the descriptions are inadequate to classify them with any certainty. Cabrera, however, notes similarities to a specimen figured by Moodie, which may be more accurately diagnosed as a cementoma.

ODONTOMA IN RECENT ANIMALS

Odontomas, to judge from published reports, occur less commonly in other mammals than in man (we are aware of the condition among the lower vertebrates only in teleost fishes). Gorlin *et al.* (1959) in an account of 487 cases of oral and pharyngeal pathosis in domestic animals noted only five instances of odontoma and teratoma (3 canine, 1 bovine, 1 ovine). In addition, previously recorded cases of a complex composite lesion in the molar region of a sheep and a compound composite odontoma in the cuspid area of a dog were cited. Hoogland (1926) reviews the literature on compound odontomas in horses and cattle, and Bullock and Curtis (1930) report lesions in rats. Colyer (1936) reports cases in a sheep and an ox.

Reports of odontomas in wild animals and those not strongly influenced by selective breeding practices are relatively less frequent. Pales (1930) reports odontomas in marmots, a Canadian porcupine, and elephants. (The upper dentition of the legendary African circus elephant 'Jumbo' appears to contain several massive odontomas.) Colyer (1936) cites cases in the Abyssinian and Cape buffaloes, a Tasmanian Devil, and a baboon. However, a supposed odontoma in a whale tooth figured by Moodie (1923, pl. 46*b*) is apparently a case of exostosis. Soft mixed odontomas (fibroblastomas) are reported in salmon by Schlumberger and Katz (1956) who also note previous records of odontomas in teleosts.

A so-called 'temporal odontoma' occurs (most often) in horses. This form is atypical in that it develops outside the oral cavity, in association with the temporal bones. The lesions, which may attain the size of a hen's egg, consist of from one to as many as 100 small imperfectly formed teeth encapsulated by fibrous tissue. They usually erupt through the skin, and sometimes affect the inner ear and produce brain disturbances (Miller and West, 1962). This lesion—if it can be properly termed an odontoma—has not been recognized in fossil material.

Among domestic animals odontomas seem most common in horses, possibly because these animals are more frequently subjected to oral examination than others, an obvious effect of the 'endearment factor' mentioned by Gorlin *et al.* (1959).

Few useful data on the distribution of odontomas in living animals are as yet available. The condition seems to occur wherever mammals are to be found. Odontomas are present in both wild and domestic animals. Their relative incidence in the sexes has not been studied. No correlation between the incidence of odontomas in animals and possible external stimuli has been suggested, but Schlumberger and Katz (1956) suggest a possible genetic factor in the fish family Salmonidae. Taxa in several orders of mammals are subject to odontomas. Whether the condition is actually more prevalent in some orders cannot be determined from the small samples so far reported.